

An example of cranial trepanation dating to the Middle Bronze Age from Ebla, Syria

Silvia Mogliazza

Italian Archaeological Expedition at Ebla. Laboratorio di Antropologia, Soprintendenza per i Beni Archeologici del Lazio, via degli Stabilimenti, 5 - 00019 Tivoli (RM), Italy

e-mail: s.mogliazza@libero.it

Summary - *This paper regards the discovery of a trepanated skull dating back to the end of the Middle Bronze Age II (1650-1600 B.C.). The skull was found in a funeral pit in the Syrian city of Ebla. A rectangular area of the frontal bone measuring approximately 50 by 45 mm was purposely surgically removed through the use of a blade. Deposition of new bone indicates that the subject survived for a long period after the surgery. This skull represents one of the oldest cases of trepanation with a quadrilateral form of incision found in the Near East.*

Keywords - *Trepanation, Ebla, Middle Bronze Age.*

Introduction

The Italian Archaeological Expedition of the University of Rome "La Sapienza", headed by Paolo Matthiae, has uncovered many human skeletal remains in the city of Ebla (Syria) in recent years. A demographic and palaeopathological project to study the human remains from this site was initiated in 2005. This work first focused on the human remains discovered in the funeral pit P.8680 of the Southern Palace (Matthiae, 2004), which dates back to the end of the Middle Bronze Age II (1650-1600 B.C.). The pit was employed for burial depositions until it was ceased to be used. In fact, archaeological investigations have established that for a certain period of time, the pit was the direct entrance of a funeral chamber. Only later, during the final phases, was this pit used for burial deposition. The excavation of this structure reached the entrance tunnel to the chamber, at that point in the excavation there was a considerable risk of the vault collapsing and the work was suspended. The archaeological evidence shows that the burials from the upper level were found in primary

burial position whereas bones found on the lower levels were mixed. The mixing of bones probably took place every time the tomb was reopened and a new burial was placed in it. The individual with a cranial trepanation (Individual 1) was the last burial to be deposited before the tomb was closed for the last time.

Materials and results

Individual 1 is a male, 45 to 55 years old. The body was in a primary posture, flexed, in an East-West orientation and left lateral position. The burial was nearly complete on recovery.

The trepanation is located on the left side of the frontal bone very near the coronal suture and the hole measures 35 by 29 mm (Figs. 1 and 2). The hole is characterized by an irregular quadrilateral perimeter which is clearly visible when laterally illuminated with a lamp (Fig. 3).

The surface of the border is irregular, rough and contains small pits of an osteitic nature, while the diploe has been completely obliterated by later deposition of bone as a result of healing. The

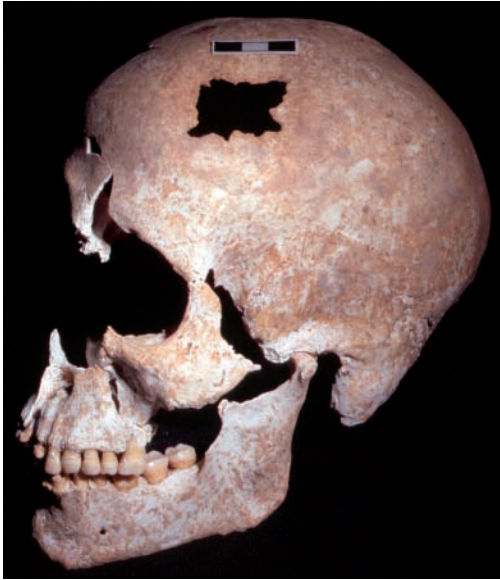

Fig. 1 - The skull of Individual 1 with the trepanation opening.

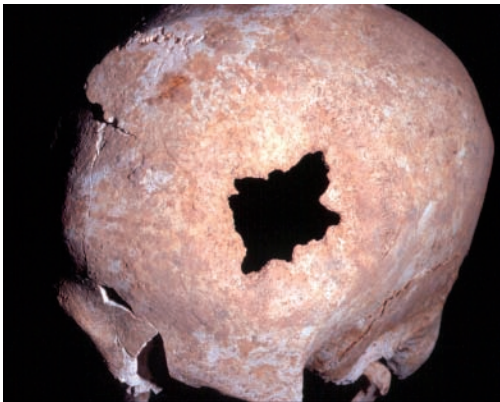


Fig. 2 - A close up of the left side of the frontal bone.

jagged borders of the hole thin out from its center, with newly placed formations of laminated tissue and bony protrusions, which are orientated centripetal to the hole. A radiological exam showed that the area of the cortical tables around the borders is spongy and thinned. Furthermore, there is also a sclerosis in the surrounding area (Fig. 4).

The skull examined is thought to have been subjected to a quadrilateral incision of the bone through the use of a blade. The dimensions of the original cranial surgically made hole can be calculated by considering the approximately rectangular sclerotic and osteitic area, which is visible on the outer surface of the skull. The cut, which was probably 50 by 45 mm in size, was followed by an extensive deposition of new bone. This partly covered the original morphology of the surgical hole.

The extensive healed area of bone suggests that the period of survival of this individual appears to be considerable. He survived long enough to produce approximately up to 15 mm of new bone growth. This hypothesis is also based on the macroscopic observation of the spongy diploe and on the internal and external characteristics of the tables. There is a considerable bone remodeling evident by the presences of bony overgrowths over the once exposed cranial diploe. The area immediately surrounding the opening is thin and therefore more transparent compared to the more marginal peripheral area (Fig. 4). In some trepanations, including this one, the borders contain a pitted area around the opening which makes the bone seem spongy in nature. This is further evidence that the subject survived for a certain period because it indicates an infection following the trepanation which was resolved as indicated by the remodeling of the borders.

Discussion

Trepanation consists of removing part of the skull without damaging the tissue below. It has been used frequently in the past in many cultures over the world and represents one of the first forms of medical surgery on the head for which there is clear evidence (Lisowsky, 1967; Arnott, 2003). Practiced since Neolithic times and widespread throughout the world, it requires a skilled intervention and a considerable technical ability (Guiard, 1930). Even today, some societies still perform this type of intervention using the same techniques adopted in prehistoric times (Oakley

et al., 1959). Literature has suggested two possible reasons for this type of practice: therapeutic and magic-ritual (Broca, 1876; Horsley, 1888; Lucas-Championnière, 1912; Moodie, 1923; Thompson, 1938; Piggott, 1940; Castiglioni, 1941). It must be stated, however, that for prehistoric cases it is impossible to distinguish between the two. Many experts consider trepanation to be a surgical intervention aimed at relieving cerebral pressure in order to cure intra-cranial illnesses, such as intra-cranial hemorrhages due to vascular lesions, hematomas due to contusion and cephalgia. Alternatively the surgery could have been carried out to remove bone fragments following skull fractures. Other experts give more weight to the theory of magic rituals, taking into consideration that many intra-cranial illnesses were thought to be due to spirits. The intervention, in this case, would be carried out to free these spirits in order to obtain a complete cure. In our case study, there are no cultural or archaeological evidence which can cast light on the motives behind the trepanation.

The principal techniques used consisted of scraping, drilling and incisions. The initial hole could be enlarged and shaped using a combination of methods such as scraping-incision or scraping-drilling. In scraping, a lithic instrument is used which has an abrasive surface. The tool is rubbed across the skull surface continuously until a perforation is obtained. In general, trepanations which adopt this technique are ellipsoidal and are surrounded by a crater-like depression. Drilling uses a pointed tool which circles the principal handle. The form and size of the opening varies according to the shape of the instrument used and the angle at which the tool is adopted. One variety of drilling consists in the so-called “ebony worker’s crown” where a burin is used to make many adjacent perforations delimiting a precise area.

For the Ebla subject the opening was performed by an incision. This technique was made using a very hard and sharp instrument. The holes, which are achieved through the progressive cutting of the surface of the skull, can be shaped in many ways: circular, fusiform and, like in this subject, quadrilateral. A metallic blade was probably



Fig. 3 - A close up of the opening which shows the complete healing of the edges with new depositions of bone with small osteitic pits.

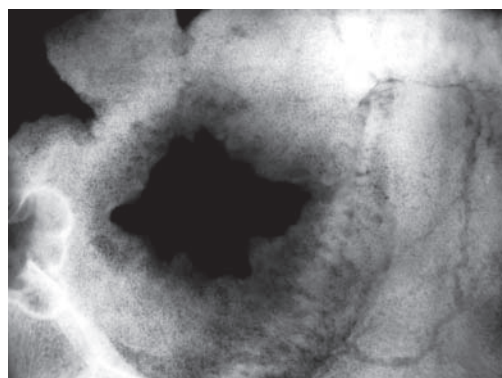


Fig. 4 - An X-ray which shows a thinning of the tables with a sclerosis of the surrounding area.

used to make four incisions at right angles to each other following the classic so-called “incaic cross” technique. The Ebla case represents one of the oldest examples so far discovered of a quadrilateral trepanation in the Near East (Tab. 1).

The subject from Ebla dates back to the end of Middle Bronze Age II. Other Syrian archaeological sites yields examples of trepanation that dates back to the Bronze Age: three skulls from Ras Shamra (Dastugue, 1962; Ferembach & Vallois, 1962), one from Tell Bi’a (Wolska, 1994) and the doubtful cases of Minet el Beida (Dastugue, 1962), Tell Mozan (Ramos, 2007) and Qatna (Canci, personal comm.).

In the Near East area the oldest cases documented, date back to the Proto-Neolithic, are found at the site of Zawi Chemi Shanidar in Iraq (Ferembach, 1970). An example of Neolithic trepanation was found in Jericho (Kurth & Roher-Ertl, 1981). Trepanations from the Chalcolithic have been found in Azor in Israel (Ferembach, 1984), in Wadi Makuq, near Jerico (Zias & Pomeranz, 1992), in South Sinai (Hershkovitz, 1987); in Anatolia at Elmali-Karatas (Angel, 1966) and six cases from Kuraçay-Höyük (Güleç, 1995). A case from the Early Bronze Age has been documented at Arad in Israel (Smith, 1990).

The example from Kültepe in Anatolia dates to the Middle Bronze Age I (Şenyürek, 1958). There are also skulls from Jericho (Oakley *et al.*, 1959; Brothwell, 1965) and Tell Beit Mirsim in Israel (Smith & Dujovny, 2004) which date back to the same period as the Ebla sample. Three skulls from the Iron Age have been recorded in Palestine at Tell Duweir (Parry, 1936; Starkey, 1936; Giles 1953) and another was found at Timna in Israel (Ferembach, 1957) dated between the Iron Age and Roman times. In these last four examples, the quadrilateral incision performed was the same as the one used for the case from Ebla.

Tab. 1 – The principal cases of trepanation in the Near East from the Neolithic to the Iron Age with a description of the type of the holes and their anatomical position.

Site	Region	Period	Description	Bibliography
Zawi Chemi Shanidar	IRAQ	Proto-Neolithic	Rounded / Frontal	Ferembach, 1970
Jericho	PALESTINE	Neolithic	Rounded / Parietal	Kurth & Roher-Ertl , 1981
Kuraçay-Höyük (6 skulls)	ANATOLIA	Early Chalcolithic	Rounded / -	Güleç, 1995
Elmali-Karatas	ANATOLIA	Chalcolithic	Rounded / -	Angel, 1966
Azor	ISRAEL	Chalcolithic	Rounded / Occipital	Ferembach, 1984
South area	SINAI	Chalcolithic	Rounded / Parietal	Hershkovitz, 1987
Wadi Makuq	PALESTINE	Chalcolithic	Rounded / Bregma	Zias & Pomeranz, 1992
Arad	ISRAEL	Early Bronze I	Rounded / Bregma	Smith, 1990
Kültepe	ANATOLIA	Middle Bronze I	Incisions / Occipital	Şenyürek, 1958
Tell Bi'a	SYRIA	Middle Bronze I	Rounded / Frontal	Wolska, 1994
Qatna	SYRIA	Middle Bronze I	Incisions / Parietal	Canci (unpublished)
Ras Shamra (2 skulls)	SYRIA	Middle Bronze	Elliptical / Sagittal Rounded / Parietal	Dastugue, 1962
Jericho (4 holes)	PALESTINE	Middle Bronze II	Rounded / Coronal (1) Rounded / Frontal (3)	Oakley <i>et al.</i> , 1959; Brothwell, 1965
Tell Beit Mirsim	ISRAEL	Middle Bronze II	Rounded / Frontal	Smith & Dujovny, 2004
Tell Mozan (2 holes)	SYRIA	Middle Bronze II	Rounded / Occipital Elliptical / Sagittal	Ramos, 2007
Ebla	SYRIA	Middle Bronze II	Quadrilateral / Frontal	
Ras Shamra (4 holes)	SYRIA	Late Bronze	Elliptical / Coronal	Ferembach & Vallois, 1962
Minet el Beida	SYRIA	Late Bronze	Rounded / Parietal	Dastugue, 1962
Tell Duweir (3 skulls)	PALESTINE	Iron Age	Quadrilateral / Parietal (2) Elliptical / Parietal (1)	Parry, 1936; Starkey, 1936; Giles, 1953
Timna	ISRAEL	Iron Age/ Roman	Quadrilateral / Frontal	Ferembach, 1957

Other cases have been found in neighboring areas including Iran (Mallin & Rathbun, 1976) and Arabian Gulf (Littleton & Frifelt, 2006). In areas like Egypt and Sudan some past cases which were considered trepanations were later recognised as pseudotrepanations in that they were found to be pathologies, traumas or taphonomic alterations. The oldest presumed case found comes from Sesebi in Sudan (Leca, 1986) which dates back to 1200 B.C. (XVII-XIX Dynasty).

Conclusion

There is little certain data regarding trepanations from Syria. This is probably due to a lack of systematic anthropological research. However, recent discoveries in Syria have revealed that this area represents one of the most active centers of cultural transformation in the medical field. The Ebla individual represents an important example of successful surgery in the Middle Bronze Age. In fact, the considerable deposition of new bone clearly indicates that the subject survived for a long period after the intervention. The successful operation and the probable introduction of a new cutting technique indicate that there were specialists capable of performing innovative surgical practices during this time in history.

The Ebla case dates back to the Middle Bronze Age, a period when cranial interventions seem to have become particularly frequent in the entire near eastern territory. However there is still little evidence to indicate why these interventions were carried out. Fortunately, recent findings in Syria will make it possible to analyse these aspects in more detail and eventually obtain more precise information regarding surgical techniques in the Near East.

Acknowledgements

I would like to thank Alessandro Canci (University of Udine), Gino Fornaciari (University of Pisa) and Robert R. Paine (Texas Tech University) for their useful paleopathological suggestions.

References

- Angel J. L. 1966. Appendix: Human skeletal remains at Karatas. In M. J. Mellink (ed.): Excavations at Karatas-Semayük in Lycia, 1965. *Am. J. Archaeol.*, (Monograph) 70: 255-257.
- Arnott R., Finger S. & Smith C.U.M. (eds.). 2003. *Trepanation: History, Discovery, Theory*. Swets and Zeitlinger, Lisse, The Netherlands.
- Broca P. 1876. Sur les trépanations préhistoriques. *Bull. Soc. Anthropol. Paris.*, Sér. 2, 11: 236-431.
- Brothwell D.R. 1965. The paleopathology of the E.B.-M.B. and Middle Bronze age remains from Jerico (1957-58 excavations). In K.M. Kenyon (ed.): *Excavations at Jerico. II. The tombs excavated in 1955-58*, pp. 685-93. British School of Archaeology, Jerusalem.
- Castiglioni A. 1941. *A history of medicine*. Knopf, New York.
- Dastugue J. 1962. Les pièces pathologiques de Ras Shamra et Minet el Beida. In C.F.A. Schaffer (ed.): *Ugaritica IV. Découvertes des XVIII et XIX campagnes, 1954-1955. Fondements préhistoriques d'Ugarit et nouveaux sondages, études anthropologiques, poteries grecques et monnaies islamiques de Ras Shamra et environ*, pp. 623-630. P. Geuthner, Paris.
- Ferembach D. 1957. A propos du crâne trépané trouvé à Timna, origine de certaines tribus Bèrberes. *Bull. Mém. Soc. Anthropol. Paris*, 8: 244-275.
- Ferembach D. 1970. Etude anthropologique des ossements humains Proto-Neolithiques de Zawi Chemi Shanidar (Irak). *Sumer*, 26: 21-64.
- Ferembach D. 1984. A propos d'une trépanation sur un fragment d'occipital humain chalcolithique trouvé à Azor (Israël). *Sep. Gracia de Orta Ser. Antropobiologica*, 3: 139-142.
- Ferembach D. & Vallois H.V. 1962. Les restes humain de Ras Shamra et Minet el Beida: etude anthropologiques. In C.F.A. Schaffer (ed.): *Ugaritica IV. Découvertes des XVIII et XIX campagnes, 1954-1955. Fondements préhistoriques d'Ugarit et nouveaux sondages, études anthropologiques, poteries grecques et monnaies islamiques de Ras Shamra et environ*, pp. 565-622. P. Geuthner, Paris.

- Giles M. 1953. *Crania from Tell El-Duweir. Lachish III. The Iron Age*. The Wellcome-Marston Archaeological Research Expedition to Near East.
- Guiard E. 1930. *La trépanation crânienne chez les néolithiques et chez les primitifs modernes*. Masson, Paris.
- Güleç E. 1995. Trepanation in ancient Anatolia: six new case studies (abstract). *Papers on Paleopathology presented to the Twenty Second Meeting of the Paleopathology Association*, Oakland, 28-29 March 1995, Paleopathology Association, p. 6.
- Hershkovitz I. 1987. Trephination: the earliest case in the Middle East. *Mitekufat Haeven. Journal of the Israel Prehistoric Society*, 20: 128-135.
- Horsley V. 1888. Trephining in the neolithic period. *Journal of Royal Anthropological Institute*, 17:100.
- Leca A.P. 1986. *La medicina egizia al tempo dei faraoni*. Ciba-Geigy, Milano.
- Littleton J. and Frifelt K. 2006. Trepanations from Oman: a case of diffusion? *Arabias Archaeology and Epigraphy*, 17: 139-151.
- Lucas-Championnière J. 1912. *Les origines de la trépanation décompressive*. Steinheil, Paris.
- Kurth G. & Roher-Ertl O. 1981. On the anthropology of the Mesolithic to Chalcolithic human remains from the Tell es-Sultan in Jericho, Jordan. In K.M. Kenyon (ed): *Excavations at Jericho III*, pp. 407-499. British School of Archaeology, Jerusalem.
- Lisowski F.P. 1967. Prehistoric and Early Historic Trepanation. In D. Brothwell & A.T. Sandison (eds): *Diseases in Antiquity. A survey of the diseases, Injuries and surgery of early populations*, pp. 651-672. C.C. Thomas, Illinois.
- Mallin R. & Rathbun T.A. 1976. A trephined skull from Iran. *Bull N. Y. Acad. Med.*, 52: 783-787.
- Matthiae P. 2004. *Le Palais Méridional dans la Ville Basse d'Ebla paléosyrienne: Fouilles à Tell Mardikh 2002-2003*, pp. 301-346. Comptes Rendus de l'Académie des Inscriptions et Belles-Lettres, Paris.
- Moodie R.L. 1923. *Paleopathology. An introduction to the study of ancient evidences of disease*. University of Illinois Press, Urbana.
- Oakley K.P, Brooke Winifred M.A, Akester A.R & Brothwell D.R. 1959. Contributions on trepanning or trephination in ancient and modern times. *Man*, 59: 93-96.
- Parry W. 1936. Three skulls from Palestine showing two types of primitive surgical holing: being the first skulls exhibiting this phenomenon that have been discovered on the mainland of Asia. *Man*, 36: 170-171.
- Piggott S. 1940. A trepanned skull of the Beaker period from Dorset and the practice of trepanning in prehistoric Europe. *Proc. Prehistoric Soc.*, 6: 112.
- Ramos L. 2007. Ancient disease and trauma: a case from Tell Mozan, Syria dating to 1600 B.C.. *Am. J. Phys. Anthropol.*, 44: 195.
- Şenyürek M. 1958. A case of trepanation among the inhabitants of the Assyrian trading colony at Kültepe. *Anatolia*, 3: 51-53.
- Smith P. 1990. The trephined skull from the Early Bronze Age period at Arad. *Eretz-Israel*, 21: 89-93.
- Smith P. & Dujovny L. 2004. Middle Bronze Age II human remains from Caves 7, 24 and 33. In S. Ben-Arieth (ed): *Bronze and Iron Age tombs at Tell Beit Mirsim*, pp. 203-205. Israel Antiquities Authority Reports, IAAR 23, Jerusalem.
- Starkey J.L. 1936. Discovery of skulls with surgical holing at Tell Duweir, Palestine. *Man*, 36: 169-170.
- Thompson C.J.S. 1938. The evolution and development of surgical instruments. IV. The trepanation, *Br. J. Surg.*, 25: 726.
- Wolska W. 1994. Zwei Fälle von Trepanation aus der altbabylonischen Zeit Syriens. *Mitteilungen der Deutschen Orient-Gesellschaft zu Berlin*, 126: 37-50.
- Zias J. & Pomeranz S. 1992. Serial Craniectomies for Intracranial Infection 5.5 Millennia Ago. *Int. J. Osteoarchaeol.*, 2: 183-186.